


PATIENT PRESENTING CLINICAL SIGNS

Lily O'Hara
 History: Grade 5-6/6 heart murmur with maximum intensity on the mitral valve. Possible eye ulcer with capillary injury.
 -Current medications: Tobramycin, Optixcare, Doxycycline, Tramadol.

SPECIES

Canine

ECHOCARDIOGRAM FINDINGS

2D, m-mode, color flow and doppler imaging is available. Mild diffuse thickening of mitral valve leaflets with minimal prolapse into the left atrial lumen. Mild eccentric mitral regurgitation with mild left atrial dilation. Normal MR velocity. Normal LV diameter with adequate myocardial function. The tricuspid valve appears normal with trace tricuspid regurgitation. Normal velocity. Normal right atrial and ventricular diameter and morphology indicating no overt evidence of pulmonary arterial hypertension. The pulmonic and aortic valves are normal in morphology and mobility. Normal pulmonic and aortic outflow velocities with laminar flow. Trace aortic and no pulmonic insufficiency. No pericardial or pleural effusion noted. No obvious cardiac masses.

BREED

Bichon Mix

SEX

Female Spayed

AGE

14 years

CARDIAC CHART
WEIGHT

13.2lbs

INTERPRETED BY

 Maggie Machen Lamy,
 DVM DACVIM
 (Cardiology)

CANINE CARDIAC PARAMETERS	MR VMAX (m/s)	TR VMAX (m/s)	LA/AO (Boon method)	LA/AO (Heart Base; Swe)	FS (%)	EF (%)	EPSS (cm)
NORMAL PARAMETER	4.5-5.5	<2.7	1.3	<1.6	28-40	40-100	<0.6
PATIENT	5.0	2.7	1.45	1.53	64	93	0.29
CANINE CARDIAC PARAMETERS	HR (BPM)	AV VMAX (m/s)	PV MAX (m/s)	BODY WEIGHT (kg)	LA 2D short axis Base view (cm)	LVIDd Avg; 2D and m-mode short axis (cm)	LVIDs Avg; 2D and m-mode short axis (cm)
NORMAL PARAMETER	50-100	0.7-1.7	0.7-1.6	BELOW	BELOW	BELOW	BELOW
PATIENT	158	2.0	1.8	6.0	2.0	2.7	0.95
*Normal chamber parameters expressed as a mean value (SD)				3	1.27 (5.3)	2.46 (2.46)	1.36 (5.5)
BODY WEIGHT DEPENDENT PARAMETERS				5	1.40 (4.5)	2.74 (5.2)	1.60 (4.7)
<i>*Note: All measurements based upon multi-modal images and methods. An average value is reported.</i>				10	1.50 (3.8)	3.27 (3.5)	2.06 (3.1)
				15	1.83 (2.0)	3.71 (2.4)	2.43 (2.1)
				20	2.02 (1.9)	4.14 (2.2)	2.80 (2.0)
				25	2.18 (2.4)	4.48 (2.9)	3.10 (2.5)
				30	2.33 (3.3)	4.83 (3.9)	3.39 (3.4)
				35	2.48 (4.3)	5.17 (5.0)	3.69 (4.5)
				40	2.62 (5.2)	5.48 (6.1)	3.96 (5.4)
				50	2.88 (7.1)	6.07 (8.3)	4.46 (7.4)

HOSPITAL NAME

 Beatties Pet Hospital
 East Hamilton

REFERRING VET

Dr. Williams

INTERPRETATION OF THE FINDINGS & FURTHER RECOMMENDATIONS

Chronic degenerative valve disease causing mild mitral and trace tricuspid regurgitation. Lack of significant left atrial enlargement indicates the current risk for complication is low. A small aortic insufficiency is noted, and a baseline BP is recommended. No concurrent issues such as systolic dysfunction or pulmonary hypertension are noted in this study.

INVOICE

28403

DATE

1/17/22

In an asymptomatic dog with no significant left atrial enlargement, no cardiac medications are clearly indicated. Assessment of progression in the future will help predict long term



PATIENT

Lily O'Hara

prognosis, which is highly variable at this stage. Omega fatty acid supplementation and mild salt restriction may be of some long-term benefit. Monitor for development of a cough, labored breathing, exercise intolerance or collapse episodes.

SPECIES

Canine

Anesthetic risk is considered mild if needed. Cardiac protective drug choices (opioid/benzodiazepine premedication, propofol or alfaxalone induction, isoflurane gas) are recommended. Pre-oxygenate for 5-10 minutes prior to induction. Monitor for arrhythmias, hypotension, and hypoxia both intra and post-operatively and intervene as necessary. Mild IV fluid restriction is recommended to avoid fluid overload. Avoid heart rate stimulating drugs such as atropine unless clinically indicated.

BREED

Bichon Mix

SEX

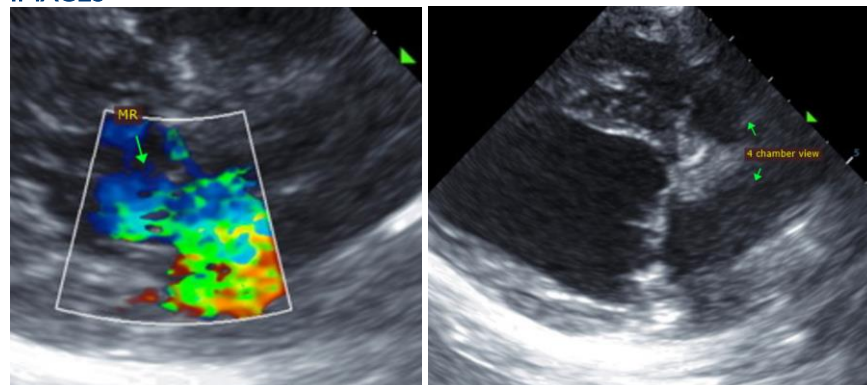
Female Spayed

Recommend conservative monitoring with a recheck echocardiogram in 6 months, sooner if any development of clinical signs.

IMAGES

AGE

14 years



WEIGHT

13.2lbs

INTERPRETED BY

Maggie Machen Lamy,
DVM DACVIM
(Cardiology)

The information and recommendations provided are based on the images presented by the referring veterinarian. No evaluation can be communicated regarding pathology that was not visible in the image/video clips provided.

IMAGING PERFORMED BY

Crystal Hill, RVT

Thank you for this referral. This report was generated using transcription software, and minor dictation errors may be present. If the clinical or image interpretation does not parallel your findings or if I can be of any further assistance, please contact me.

HOSPITAL NAME

Beatties Pet Hospital
East Hamilton

Maggie Machen Lamy, DVM
Diplomate of the American College of Veterinary Internal Medicine (Cardiology)
info@sonopath.com

REFERRING VET

Dr. Williams

INVOICE

28403

DATE

1/17/22